

Clinical Image

Intra-gastric Erosion of an Adjustable Gastric Band

Timothy R. Koch* and Timothy R. Shope

Center for Advanced Laparoscopic General & Bariatric Surgery, USA

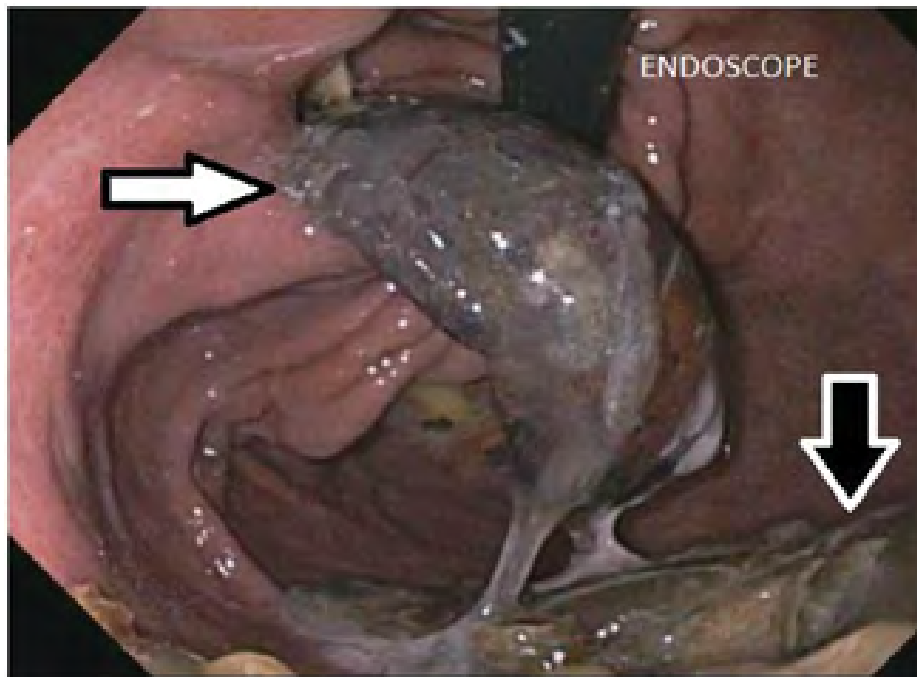


Figure:1 Gastric Band Erosion.

The adjustable gastric band has been deflated. The intra-gastric location of the adjustable gastric band is indicated by the white arrow. The plastic buckle of the adjustable band is external to the stomach and is likely adjacent to the anterior wall of the stomach. The presence of a gastric bezoar on the greater curvature of the stomach is indicated by the black arrow (Figure). The endoscope being used for this upper endoscopy is seen entering the stomach at the gastroesophageal junction at the top of the picture.

***Corresponding author:** Timothy R. Koch, Center for Advanced Laparoscopic General & Bariatric Surgery, MedStar-Washington Hospital Center and Georgetown University School of Medicine, Washington, USA; Tel: 1-202-877-7788; Fax: 1-877-680-8198; Email: timothy.r.koch@medstar.net

Citation: Koch TR, Shope TR (2016) Intra-gastric Erosion of an Adjustable Gastric Band. *Int J Clin Med Imaging* 3: 487. doi:[10.4172/2376-0249.1000488](https://doi.org/10.4172/2376-0249.1000488)

Copyright: © 2016 Koch TR, et al. This is an open-access article distributed under the terms of the Creative Commons Attribution License, which permits unrestricted use, distribution, and reproduction in any medium, provided the original author and source are credited.
