

Clinical-Medical Image

Malformation of the External Ear: Microtia or Major Aplasia

Eric Michel Charlemagne*

General Practitioner, Morocco

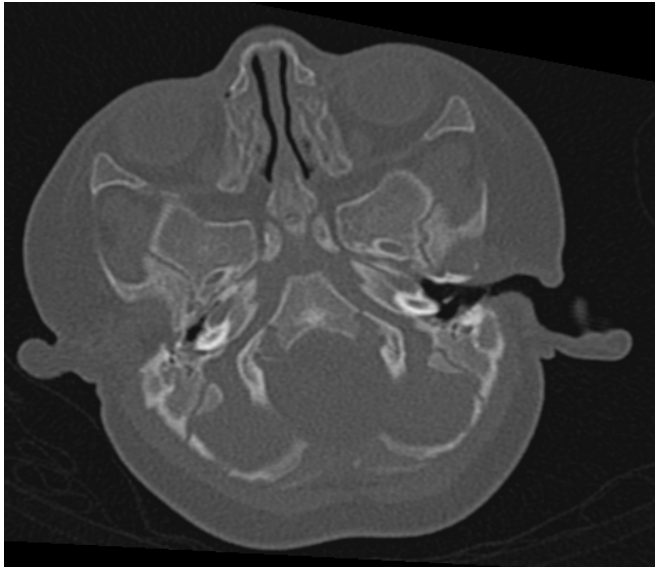


Figure 1: Microtia with vertical chondro-cutaneous remnant without identifiable relief.

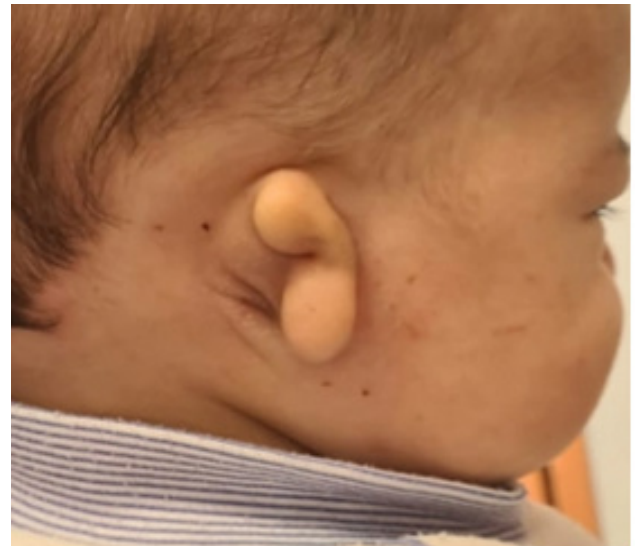

Figure 2: Axial section: Agenesis of the right external auditory canal.

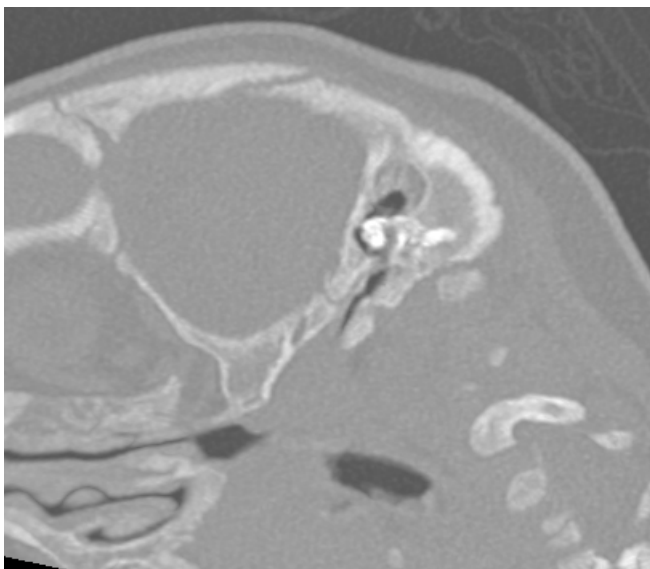


Figure 3: MIP reconstruction in sagittal section: Uncudo-malleolar block and hypoplasia of the right tympanic cavity.

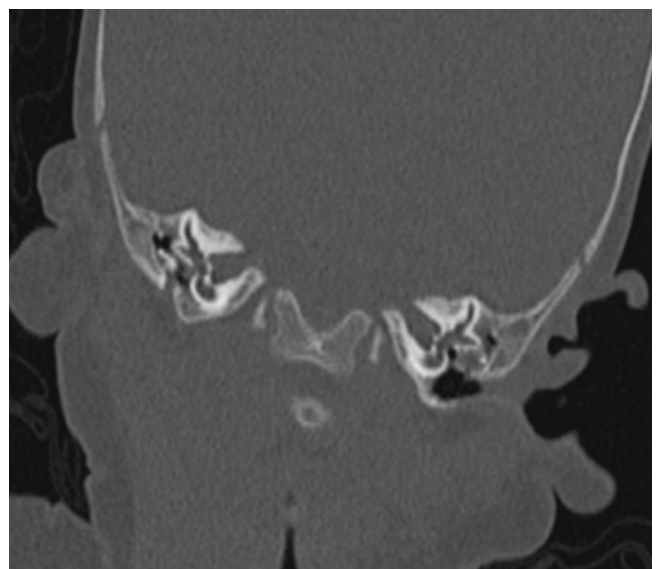


Figure 4: Coronal section with normal appearance of the inner ear structures.

Date of Submission: 16 December 2022, Manuscript No. *ijcni-22-83884*; **Editor assigned:** 17 December 2022, Pre QC No. *P-83884*; **Reviewed:** 20 December 2022, QC No. *Q-83884*; **Revised:** 24 December 2022, Manuscript No. *R-83884*; **Published:** 30 December 2022, DOI: [10.4172/2376-0249.1000861](https://doi.org/10.4172/2376-0249.1000861)

***Corresponding author:** Eric Michel Charlemagne, General Practitioner, Morocco, Tel: + 212600714720; E-mail: ericmichelkessi@gmail.com; kessieric1@gmail.com

Citation: Charlemagne EM. (2022) Malformation of the External Ear: Microtia or Major Aplasia. *Int J Clin Med Imaging* 9:861.

Copyright: © 2022 Charlemagne EM. This is an open-access article distributed under the terms of the Creative Commons Attribution License, which permits unrestricted use, distribution, and reproduction in any medium, provided the original author and source are credited.

Clinical-Medical Image

Abstract

Microtia is an abnormality in the development of the outer ear. The degrees of microtia vary according to the stage of development of the pinna and can range from a small ear with all the appropriate cartilage (degree I) to a small ear «bud » with little or no cartilage. Agenesis of the external auditory canal is the failure of the auditory canal to develop, often associated with a middle ear anomaly.

Introduction

Microtia is an abnormality in the development of the outer ear. The degrees of microtia vary according to the stage of development of the pinna and can range from a small ear with all the appropriate cartilage (degree I) to a small ear «bud » with little or no cartilage. Agenesis of the external auditory canal is the failure of the auditory canal to develop, often associated with a middle ear anomaly.

Microtia is a congenital malformation of the external ear, most often seen in male patients, and occurs sporadically or inherited. It is characterized by the presence of small, abnormally hemmed ears, and is often associated with atresia or stenosis of the ear canal, attention deficit disorders and delayed language acquisition. This rare condition is unilateral in 79-93% of cases, with 60% involving the right ear. The size of the outer ears varies from stage I, where the ear is simply smaller than normal, to stage IV, also known as anotia, characterized by a complete absence of the outer ear and ear canal [1-4].

Microtia consists of a remnant lobule that is verticalized and frontalized, topped by a small, misshapen cartilaginous mass that when dissected resembles the extreme shape of a horned auricle a few millimeters high (Figure 1).

Major malformation of the auricle, it is often associated with other malformations of branchial origin of which the most frequent are agenesis of the external auditory canal, ossicular malformations and mandibular hypoplasia [2]. External auditory canal anomalies can range from total absence of the canal (Figure 2) as in the case of major aplasia of the auricle, to isolated, moderate congenital narrowing, without any repercussions on auditory function. The existence of a significant conductive hearing loss of more than 30 dB should point to an associated middle ear malformation of the « aplasia minor » type (Figure 3).

In addition, due to the absence of the external auditory canal, eardrum or ossicles, hearing is frequently impaired. However, the inner part of the ear is rarely affected (Figure 4) and the auditory nerve remains intact in the vast majority of cases of microtia [3].

Keywords: Malformation; Microtia; External ear; Agenesis; External auditory canal

References

- [1] Denoyelle, F. (2007) Pathologie congénitale de l'oreille externe. *In EMC*, 2: 1-12
- [2] Bonilla A. (2018) Reconstruction de la microtie pédiatrique avec côte autologue. *Cliniques de chirurgie plastique faciale d'Amérique du Nord*, 26: 57-68.
- [3] Teissier N, Benchaa T, Elmaleh M, Van Den Abbeele T. (2008) Malformations congénitales de l'oreille externe et de l'oreille moyenne. *EMC-Oto-Rhino-Laryngologie*, 3: 1-11.
- [4] Alasti F, Van Camp, G. (2009) Génétique de la microtie et des syndromes associés. *Tourillon de génétique médicale*, 46: 361-369.