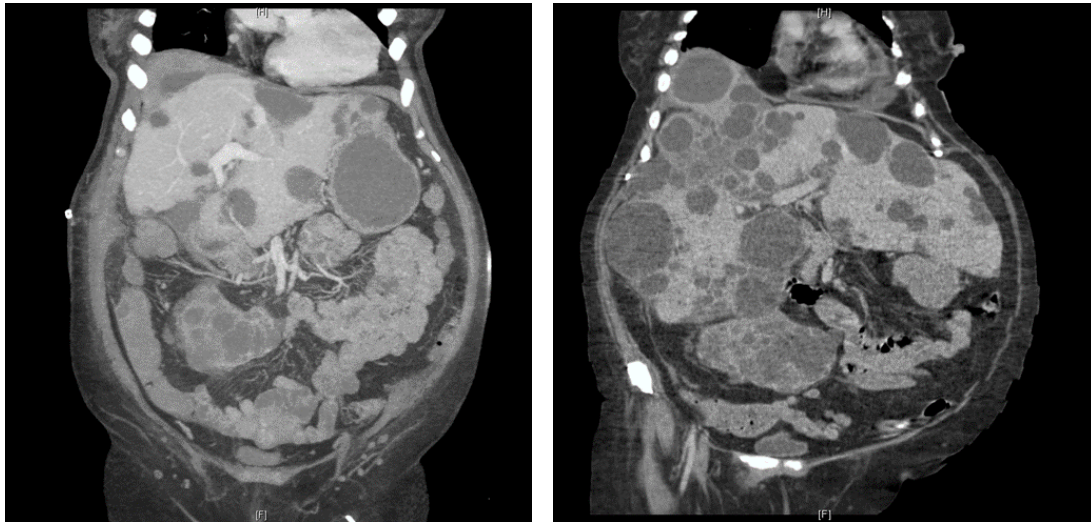


Clinical Image

Title: Massive Polycystic Liver and Kidney Disease

Jennifer A. Berumen*, Marc L. Melcher and C.A. Bonham
Stanford University, USA



These are CT images of 60 year old woman with polycystic liver and kidney disease complicated by end-stage renal disease who was admitted for enterococcus bacteremia. The first image reveals massive polycystic liver and kidneys. The liver has at least two cysts with stranding suspicious for infection in the dome. After treatment with antibiotics a formal right hepatectomy was performed. Since the cysts were fused to diaphragm, a partial diaphragmatic resection was required. The second image shows the remaining left lobe of liver and the decompressed abdomen. The patient was 10 kg lighter after resection.

*Corresponding author: Jennifer A. Berumen, Stanford University, Palo Alto, CA 94304, USA, E-Mail: jberumen@stanford.edu

Copyright: © 2014 Berumen JA. This is an open-access article distributed under the terms of the Creative Commons Attribution License, which permits unrestricted use, distribution, and reproduction in any medium, provided the original author and source are credited.