

Clinical Image

Massive Verrucous Squamous Cell Carcinoma of the Perineum

Shah RN*

Rowan University, 201 Mullica Hill Road, Glassboro, New Jersey 08028, USA

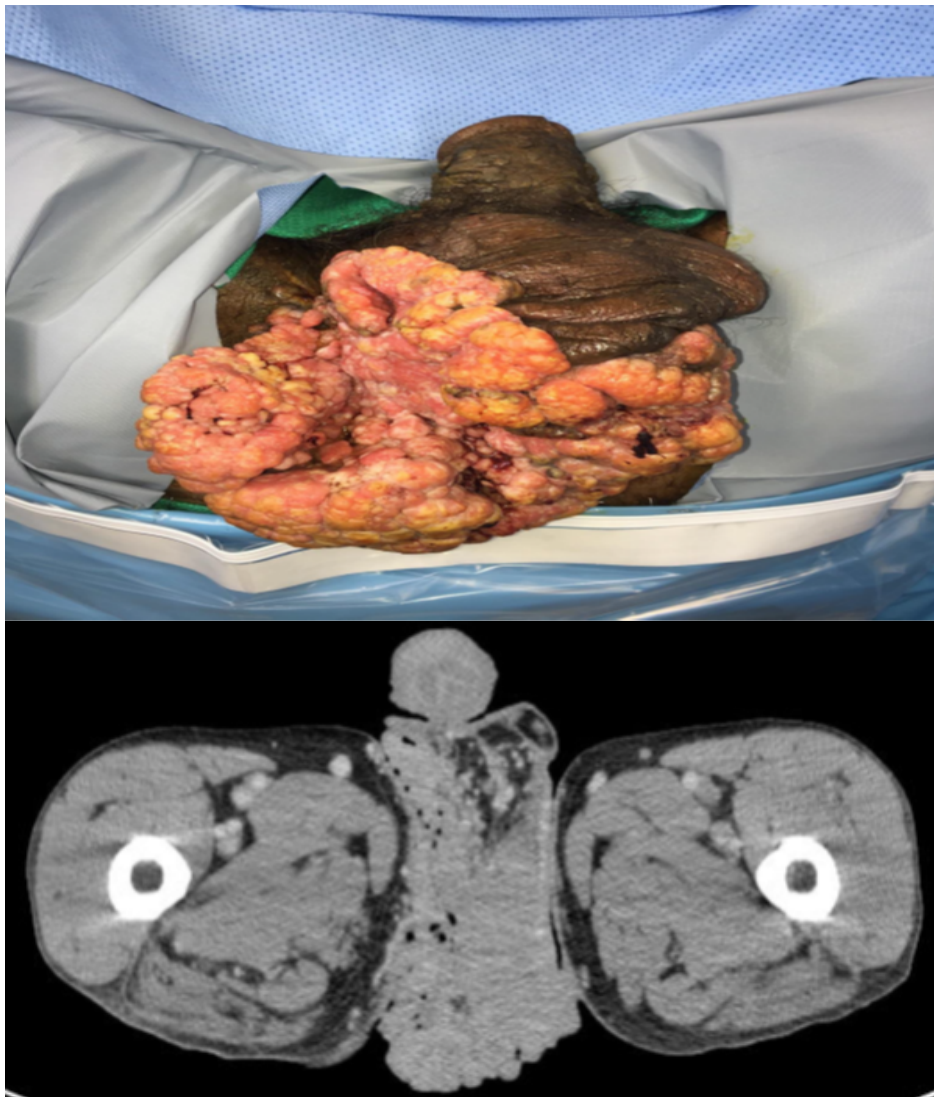


Figure 1: Massive tan-red fungating mass with a warty appearance extending from the inferior scrotum to the perineum above the rectum.

Figure 2: Computed tomography scan with intravenous contrast demonstrating bilateral inguinal lymphadenopathy and a giant mass originating from the inferior portion of the scrotum.

A 55-year-old male presented with a 5 year history of a large fungating mass on his scrotum and left medial thigh that had begun to grow rapidly over the past 1 month. He also noticed marked weight loss during this time period. He denied any lower urinary tract symptoms, pain in the perineum.

*Corresponding author: Ruchit N Shah, Rowan University, 201 Mullica Hill Road, Glassboro, New Jersey, 08028, USA, Tel: +856-256-4000; E-mail: shah121@rowan.edu

Citation: Shah RN (2017) Massive Verrucous Squamous Cell Carcinoma of the Perineum. *Int J Clin Med Imaging* 3: 535. doi:[10.4172/2376-0249.1000535](https://doi.org/10.4172/2376-0249.1000535)

Copyright: © 2017 Shah RN. This is an open-access article distributed under the terms of the Creative Commons Attribution License, which permits unrestricted use, distribution, and reproduction in any medium, provided the original author and source are credited.