

Clinical Image

Myriad Imaging Appearances of Biliary Hydatidosis

Sadalage A, Kiran S*, Gupta D and Shukla A

Department of Gastroenterology, Seth GS Medical College and KEM Hospital, Mumbai, India

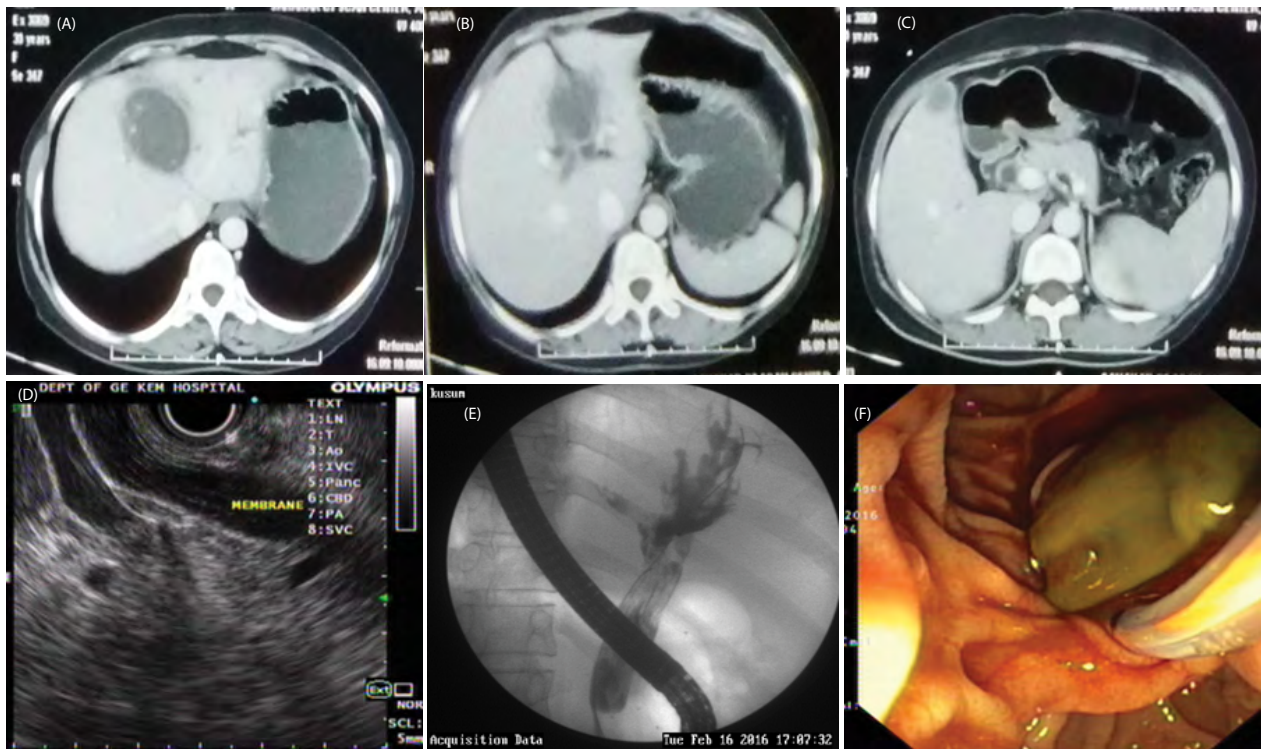


Image A-C: CECT scan shows a 5 × 4 cm cystic lesion in segment 4 of liver with peripheral calcification and communication with one of the peripheral branches of left hepatic duct. Common bile duct diameter is 12 mm.

Image D: EUS shows CBD of 12 mm with longitudinal floating membranes in common bile ducts.

Image E: Cholangiogram showing longitudinal filling defects with cystobiliary communication.

Image F: Balloon sweeps with retrieval of greenish membranes.

A 35 years old lady, farmer by occupation, presented to the outpatient department with intermittent pain in right upper quadrant for the last 3 months which was mild to moderate intensity, dull ache, non-radiating with occasional nausea and non-bilious vomiting, no relation of pain to meals. She had experienced similar episodes of pain 3 years back for 1 year and was managed conservatively. Pain was not associated with fever, jaundice, abdominal distension, lump in abdomen or altered sensorium.

On examination she was conscious, afebrile and her vitals were normal. On per abdominal examination she had hepatomegaly. There was no evidence of splenomegaly, ascites or lump in abdomen.

Investigations revealed normal haemogram and renal function tests. Liver function tests revealed normal bilirubin with elevated aspartate aminotransferase [180 U/L (40U/L)], alanine aminotransferase [97U/L (40U/L)] and alkaline phosphatase [564U/L (91U/L)].

Contrast enhanced computed tomography (CECT) showed well defined cystic lesion of size 5 × 4 cm in segment 4 of liver with peripheral calcification, showing communication with one of the peripheral branches of left hepatic duct with intrahepatic biliary radicle dilatation (IHBRD) and common bile duct dilatation up to 12 mm (Image A-C). In view of dilated common bile duct up to 12 mm and normal bilirubin, endoscopic ultrasonography examination (EUS) was planned. It showed normal gall bladder with common bile duct diameter of 11 mm with presence of longitudinal floating membranes within CBD (Image D). She underwent

*Corresponding author: Kiran S, Department of Gastroenterology, Seth GS Medical College and KEM Hospital, Mumbai, India; Tel: 022-2410-7034; Email: drvjkirans@yahoo.co.in

Citation: Sadalage A, Kiran S, Gupta D, Shukla A (2016) Myriad Imaging Appearances of Biliary Hydatidosis. *Int J Clin Med Imaging* 3: 500. doi:10.4172/2376-0249.1000500

Copyright: © 2016 Sadalage A, et al. This is an open-access article distributed under the terms of the Creative Commons Attribution License, which permits unrestricted use, distribution, and reproduction in any medium, provided the original author and source are credited.

endoscopic retrograde cholangiography (ERCP) which revealed CBD of 15 mm with longitudinal filling defects with cystobiliary communication (Image E). On flushing and suctioning, green membranes were seen oozing from papilla (Image F). A 10 Fr x 10 cms plastic biliary stent was placed. Post biliary stenting, she was given Tablet albendazole 400 mg once a day for 3 months and repeat ERCP with cholangiogram was performed. It showed normal CBD with no filling defects. Her CBD stent was removed and discharged in clinically stable condition after stent removal.