

Clinical-Medical Image

## Pelvic Kidney Revealed by Bone Scintigraphy: Interest of SPECT/CT Acquisition

Nadia Abaouz\*, Hakim Bennani and Amal Guensi

Department of Nuclear Medicine University Hospital IBN ROCHD, Casablanca, Morocco

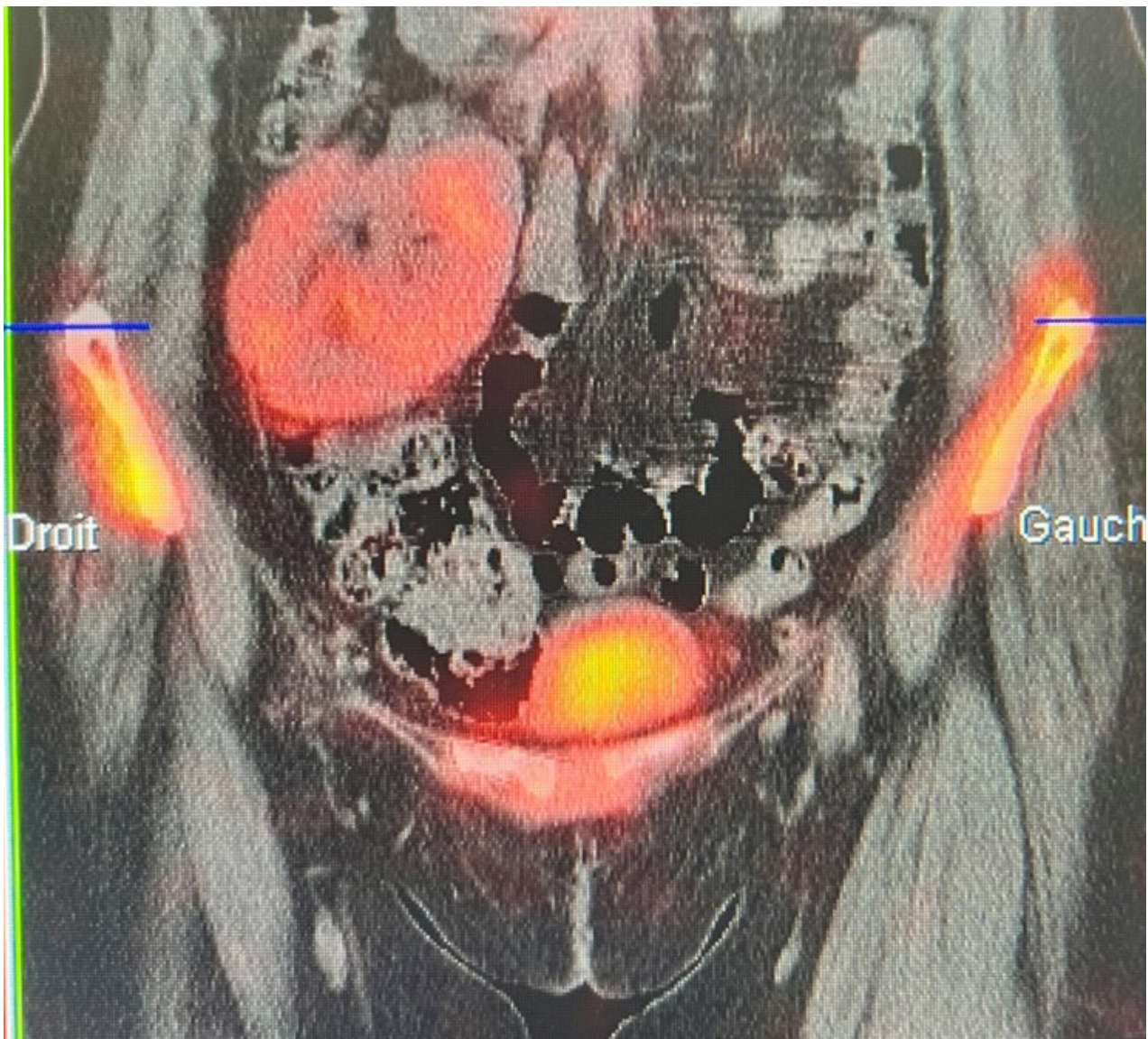


Figure 1: Osteoblastic metastasis.

**Received:** 16 December 2022, Manuscript No. ijcmi-22-86757; **Editor assigned:** 17 December 2022, Pre QC No. P-86757; **Reviewed:** 20 December 2022, QC No. Q-86757; **Revised:** 24 December 2022, Manuscript No. R-86757; **Published:** 30 December 2022, DOI: 10.4172/2376-0249.1000862

\***Corresponding author:** Nadia Abaouz, Department of Nuclear Medicine University Hospital IBN ROCHD, Casablanca, Morocco, Tel: + 212641911608; E-mail: nadia.abaouz@usmba.ac.ma

**Citation:** Abaouz N. (2022) Pelvic Kidney Revealed by Bone Scintigraphy: Interest of SPECT/CT Acquisition. *Int J Clin Med Imaging* 9:862.

**Copyright:** © 2022 Abaouz N. This is an open-access article distributed under the terms of the Creative Commons Attribution License, which permits unrestricted use, distribution, and reproduction in any medium, provided the original author and source are credited.

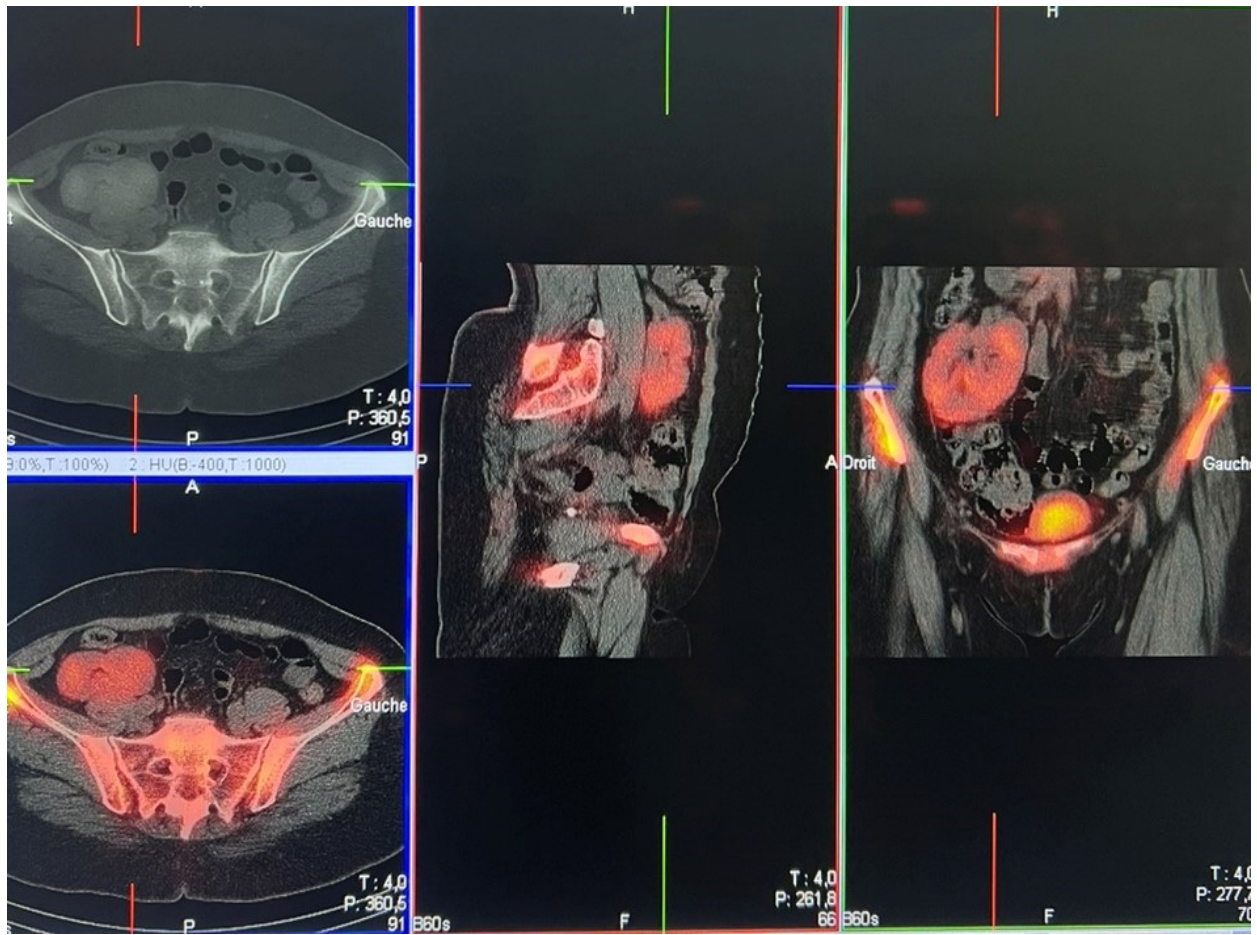


Figure 2: Bony pelvis or sacroiliitis in a patient with an ectopic pelvic kidney.

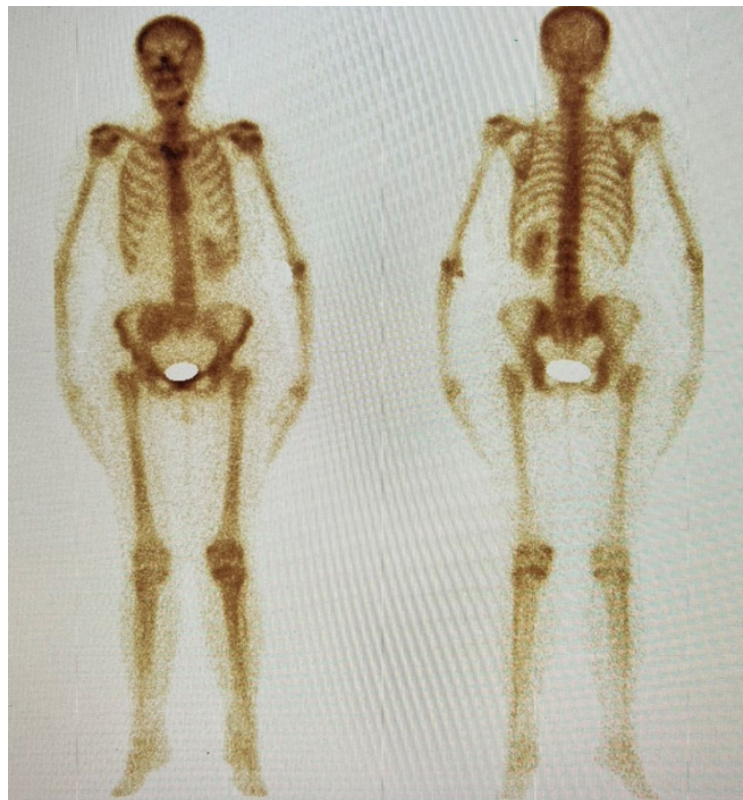

Figure 3: Bone scintigraphy.

## Clinical-Medical Image

The incidence of the pelvic kidney is reported as 1:2100-1:3000 in the autopsy series [1] although the exact incidence may be difficult to determine because of the clinically silent nature in many cases. The objective is to highlight the interest of scintigraphy to  $^{99m}\text{Tc}$ -HMDP in the fortuitous discovery of this type of malformation through the case of a 65-year-old female patient, followed for right breast cancer. The patient was referred to the nuclear medicine department for a bone scan evaluation. The whole-body scan revealed a large area of intense uptake tracer in the region of the right sacroiliac (SI) joint which appeared like an osteoblastic metastasis at first glance. Elsewhere, a globally homogeneous and symmetrical distribution of the radiotracer is noted on the rest of the bone segments explored. The SPECT/CT examination showed the renal nature of the iliac uptake and is therefore in favor of an ectopic kidney with a right iliac location.

Bone scintigraphy is widely used to detect abnormal osteoblastic activity in various diseases especially to detect bony metastases [2]. SPECT/CT can be useful instead of a planar scan for differentiation of metastases in the bony pelvis or sacroiliitis in a patient with an ectopic pelvic kidney (Figures 1-3).

**Keywords:** Breast cancer; Bone scintigraphy; SPECT/CT; Pelvic kidney; Bone metastasis

## References

- [1] Bauer SB. (2002) Anomalies of the upper urinary tract. *Campbell's Urology*, 1894
- [2] Bhuiyan MMAZ, Sarker AK, Choi H, Suh M, Cheon GJ. (2019) Pelvic kidney mimicking skeletal metastasis on bone scan-interesting image. *Bangladesh J Nuclear Med*, 22: 155-156.