

E-poster Presentation

Stepwise Excavation A conservative Community-Based Dental Treatment of Deep caries To Preserves the Tooth Vitality

Jami TR

The Saudi Board in advanced Restorative Dentistry [SSC-(Dent) Resto] Former(SB-ARD) 2012

Umm Al-Qura University Medical center The Saudi Board in advanced Restorative Dentistry [SSC-(Dent) Resto] Former(SB-ARD) 2012

Umm Al-Qura University Medical center

Introduction

Operative dentistry not only requires technical expertise and an in-depth understanding of materials science, but knowledge in cariology and pulp biology is also essential. Treatment of deep caries lesions approaching a healthy pulp presents a significant challenge to the practitioner. The traditional management of carious lesions of any kind dictates the removal of all infected and affected dentin to prevent further cariogenic activity and provide a well-mineralized base of dentin for restoration. Pulp vitality is extremely important for the tooth viability, since it provides nutrition and acts as biosensor to detect pathogenic stimuli. In 1938, Bodecker introduced the Stepwise Excavation technique for treatment of teeth with deep caries for preservation of pulp vitality and conservative. Stepwise Excavation has gained a growing interest in the recent years from different researchers due to advances made in techniques and dental materials with good sealing ability and antibacterial properties. Clinical study on stepwise excavation of deep carious lesions in vital permanent teeth: a 12-month follow-up study shown this technique is a conservative community based treatment.

Aim

The aim of this presentation is to clarify that the use of stepwise excavation technique for treatment of teeth with deep caries for preservation of pulp vitality by isolation any remaining bacteria will have died, residual infected dentin as well as affected dentin will have demineralized and reparative dentin will have been generated so diminishing progression of the lesion or even arresting it.

Materials and Methods

Female patients

Age: 13-25 years

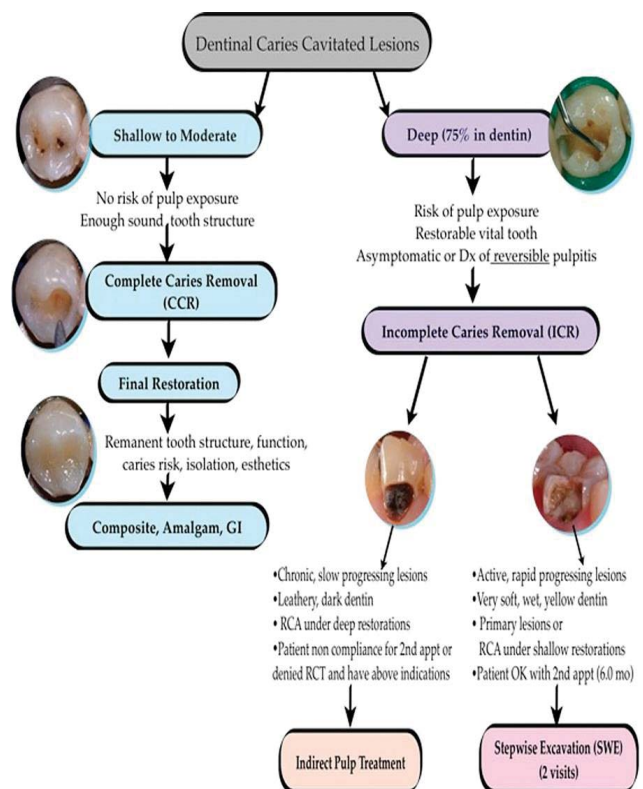
Inclusion criteria

-Examination & history of complains The material comprised 35 teeth with deep carious lesions at risk of pulp exposure if the demineralized dentin was eliminated completely

-Deep dentinal lesions likely to result in pulp exposure during single excavation

- Clear evidence of pulp vitality and no evidence of irreversible pulpitis
- No history of spontaneous or prolonged pain
- Positive pulp vitality test (electric, thermal, mechanical).
- Negative to percussion/palpation.
- Radio graphically: >75% through dentin and no periradicular pathosis.
- Reliable patient controls and follow up in place.

This study reports results from treated deep carious lesions by using stepwise excavation, access to the caries was gained and the periphery of the cavity made completely caries free. Soft, wet and pale coloured dentine was left pulpally, which has



Management of Dentinal Caries Cavitated Lesions

previously been shown to be heavily infected. The cavity was lined with calcium hydroxide or MTA and restored with glass ionomer and left for 6–12 months. After this period, cavities were re-entered and the dentine in all teeth was found to be darker in colour, harder and drier in consistency.

Results

These findings would imply that by removing some of the carious biomass and sealing the remaining caries from extrinsic substrate and oral bacteria, the caries left behind after the first excavation had become less active. This allows time for pulp-dentine complex reactions to take place so that at the second excavation visit, there is less likelihood of pulpal exposure. It has also been suggested that by changing the cavity environment from an active lesion into the condition of a more slowly progressing lesion, this will be accompanied by more regular tubular tertiary dentine formation. In a study survival rate for permanent molars 93% shown that treatment of the teeth with this technique will decrease the number of pulpal exposure during carious tissue removal from teeth with deep caries lesions. This technique is a conservative community based treatment which helps the public dental health with less expense while maintaining pulp vitality.

Conclusion

In cases of deep caries lesions, total removal of carious tissue can cause accidental pulp exposure, which can be avoided by using the stepwise excavation technique. This consists of the partial excavation of contaminated dentin application of biomaterials or 'bio-treatment of deep carious lesions' can be considered as an effective method to restore the involved tooth both biologically and functionally with long-term pulp vitality. In systematic review survival rate for permanent teeth shown that treatment of the teeth with this technique will decrease the number of pulpal exposure during carious tissue removal from teeth with deep caries lesions. This technique is a conservative community based treatment which helps the public dental health with less expense while maintaining pulp vitality.

References

1. Ricketts D, Management of the deep carious lesion and the vital pulp dentine complex. *BDJ, british dental journal*, volume 191: 11
2. Hayashi M, Fujitani M, Yamaki C, Momoi Y, EBD (2011) In deep cavities stepwise excavation of caries can preserve the pulp 12: 3
3. Verdugo PMO (2014) University of Iowa, Eight-year report of stepwise excavation procedure outcomes in a US academic setting.