

Clinical Image

Title: Surgery of a Hydatid Cyst of the Left Ventricle

Ben Jmaà Hèla¹, Bouassida Abir¹, Dhouib Faten¹, Ben Jmaà Tarak², Souissi Iheb³, Masmoudi Sayda¹, Elleuch Nizar¹, Ben Jmaà Mounir², Karoui Abdelhamid³ and Frikha Imed¹

¹Department of Cardiovascular and Thoracic Surgery, Habib Bourguiba Hospital, Sfax, Tunisia

²Department of Infectious Diseases, Hedi Chaker Hospital, Sfax, Tunisia

³Department of Anesthesiology, Habib Bourguiba Hospital, Sfax, Tunisia

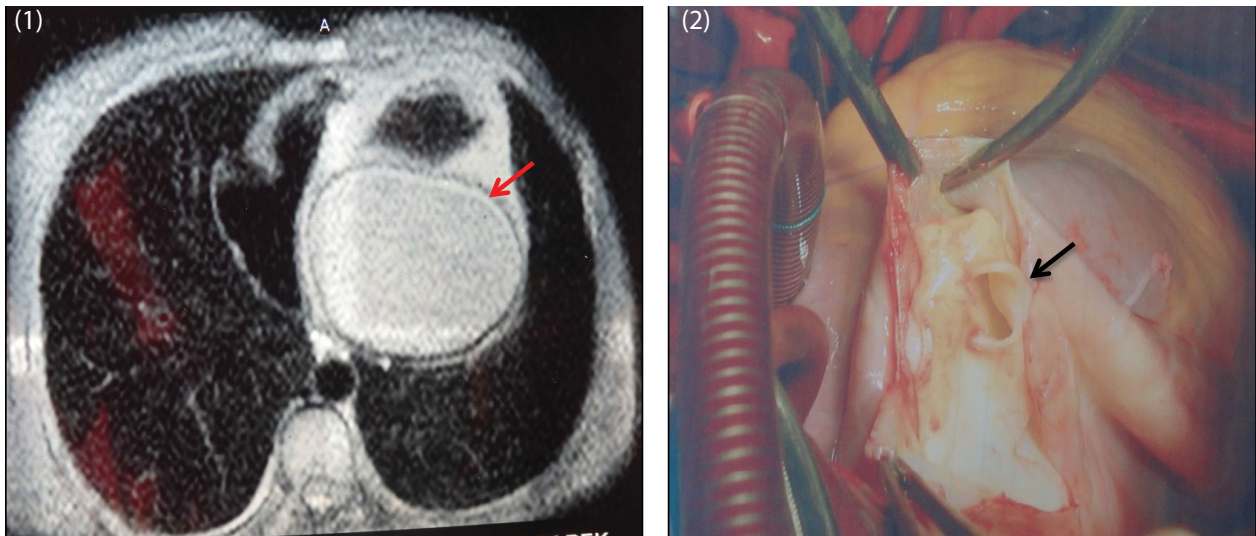


Figure 1: Thoracic magnetic resonance imaging revealing a giant left ventricular hydatid cyst (arrow).

Figure 2: Intraoperative view showing the cystic cavity of the inferior wall of the left ventricle (arrow).

A fifteen-year-old patient, with no past medical history, was admitted to the cardiology department for dyspnea occurring at the effort. Physical examination of the patient showed no signs of cardiac failure, with a normal cardiac and pulmonary auscultation. Electrocardiogram revealed a sinus rhythm with tachycardia. Chest radiography showed no cardiomegaly and no mediastinal or pulmonary opacity. So, a trans-thoracic echocardiography was performed. It confirmed a huge cystic formation measuring 9 cm of diameter, located into the posterior wall of the left ventricle. Diagnosis of hydatidosis was suspected, and thoraco-abdominal magnetic resonance imaging was performed. It revealed a huge cyst occupying the posterior and the inferior wall of the left ventricle (Figure 1), without hepatic involvement. So, our patient was operated under cardiopulmonary bypass between the ascending aorta and the two venacava. Cysto-pericystectomy of the sous-epicardic mass was done after exposure of the inferior wall of the heart (Figure 2). Then, the residual cavity was repaired by direct suture. The postoperative period was uneventful with resolution of the dyspnea.